

CHAPTER 22

ACTIONS OF THE RESPIRATORY MUSCLES

André de Troyer

The so-called respiratory muscles are those muscles that provide the motive power for the act of breathing. Thus, although many of these muscles are involved in a variety of activities, such as speech production, cough, vomiting, and trunk motion, their primary task is to displace the chest wall rhythmically to pump gas in and out of the lungs. The present chapter, therefore, starts with a discussion of the basic mechanical structure of the chest wall in humans. Then, the action of each group of muscles is analyzed. For the sake of clarity, the functions of the diaphragm, the intercostal muscles, the muscles of the neck, and the muscles of the abdominal wall are analyzed sequentially. However, since all these muscles normally work together in a coordinated manner, the most critical aspects of their mechanical interactions are also emphasized.

CHEST WALL

The chest wall can be thought of as consisting of two compartments—the rib cage and the abdomen—separated from each other by a thin musculotendinous structure, the diaphragm¹ (Figure 22-1). These two compartments are mechanically arranged in parallel. Expansion of the lungs, therefore, can be accommodated by expansion of either the rib cage or the abdomen or of both compartments simultaneously.

The displacements of the rib cage during breathing are essentially related to the motion of the ribs. **Each rib articulates by its head with the bodies of its own vertebra and of the vertebra above and by its tubercle with the transverse process of its own vertebra. The head of the rib is very closely connected to the vertebral bodies by radiate and intraarticular ligaments,** such that only slight gliding movements of the articular surfaces on one another can take place. Also, the neck and tubercle of the rib are bound to the transverse process of the vertebra by short ligaments that limit the movements of the costovertebral joint to slight cranial and caudal gliding. As a result, the costovertebral and costovertebral joints together form a hinge, and the respiratory displacements of the rib occur primarily through a rotation around the long axis of its neck, as shown in Figure 22-2A. However, this axis is oriented laterally, dorsally, and caudally. In addition, the ribs are curved and slope

caudally and ventrally from their costovertebral articulations, such that their ventral ends and the costal cartilages are more caudal than their dorsal parts (Figure 22-2B, C). When the ribs are displaced in the cranial direction, their ventral ends move laterally and ventrally as well as cranially, the cartilages rotate cranially around the chondrosternal junctions, and the sternum is displaced ventrally. Consequently, there is usually an increase in both the lateral and the dorsoventral diameters of the rib cage (see Figure 22-2B, C). Conversely, a displacement of the ribs in the caudal direction is usually associated with a decrease in rib cage diameters. As a corollary, the muscles that elevate the ribs as their primary action have an inspiratory effect on the rib cage, whereas the muscles that lower the ribs have an expiratory effect on the rib cage.

It is notable, however, that although all the ribs move predominantly by rotation around the long axis of their necks, the costovertebral joints of ribs 7 to 10 have less constraint on their motion than the costovertebral joints of ribs 1 to 6. The long cartilages of ribs 8 to 10 also articulate with one another by small synovial cavities rather than with the sternum. Hence, whereas the upper ribs tend to move as a unit with the sternum, the lower ribs have some freedom to move independently. In both animals and humans, deformations of the rib cage may therefore occur under the influence of muscle contraction or other forces.

The respiratory displacements of the abdominal compartment are more straightforward than those of the rib cage because if one neglects the 100 to 300 mL of abdominal gas, its contents are virtually incompressible. This implies that any local inward displacement of its boundaries results in an equal outward displacement elsewhere. Furthermore, many of these boundaries, such as the spine dorsally, the pelvis caudally, and the iliac crests laterally, are virtually fixed. The parts of the abdominal container that can be displaced are thus largely limited to the ventral abdominal wall and the diaphragm. When the diaphragm contracts during inspiration (see below), its descent usually results in an outward displacement of the ventral abdominal wall; conversely, when the abdominal muscles contract, they cause in general an inward displacement of the belly wall, resulting in a cranial motion of the diaphragm into the thoracic cavity.

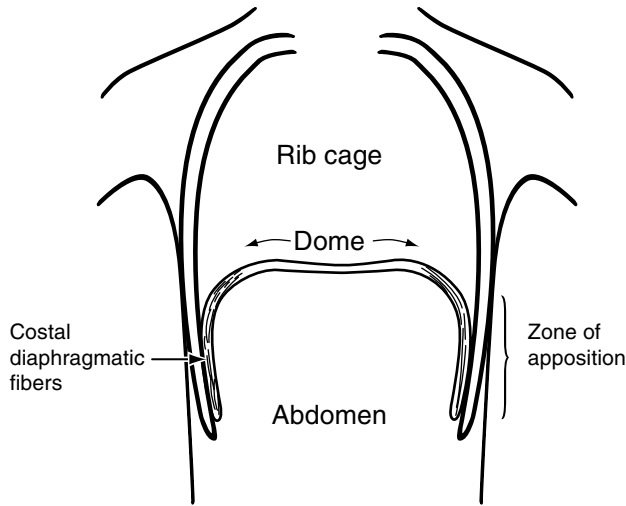


FIGURE 22-1 Frontal section of the chest wall at end-expiration. Note the cranial orientation of the costal diaphragmatic fibers and their apposition to the inner aspect of the lower rib cage (zone of apposition).

DIAPHRAGM

FUNCTIONAL ANATOMY

Anatomically, the diaphragm is unique among skeletal muscles in that its muscle fibers radiate from a central tendon to insert peripherally into skeletal structures. The crural (or vertebral) portion of the diaphragmatic muscle inserts on the ventrolateral aspect of the first three lumbar vertebrae and on the aponeurotic arcuate ligaments, and the costal portion inserts on the xiphoid process of the sternum and the upper margins of the lower six ribs. From their insertions, the costal fibers run cranially, so that they are directly apposed to the inner aspect of the lower rib cage (see Figure 22-1); this is the so-called “zone of apposition” of the diaphragm to the rib cage.² Although the older literature suggested the possibility of an intercostal motor innervation of some portions of the diaphragm, it is now clearly established that its only motor supply is through the phrenic nerves, which, in humans, originate in the third, fourth, and fifth cervical segments.

ACTIONS OF THE DIAPHRAGM

As the muscle fibers of the diaphragm are activated during inspiration, they develop tension and shorten. As a result, the axial length of the apposed diaphragm diminishes and the dome of the diaphragm, which essentially corresponds to the central tendon, descends relative to the costal insertions of the muscle. The dome of the diaphragm remains relatively constant in size and shape during breathing, but its descent has two effects. First, it expands the thoracic cavity along its craniocaudal axis. Hence, pleural pressure falls and, depending on whether the airways are open or closed, lung volume increases or alveolar pressure falls. Second, it produces a caudal displacement of the abdominal viscera and an increase in abdominal pressure, which, in turn, pushes the ventral abdominal wall outward.

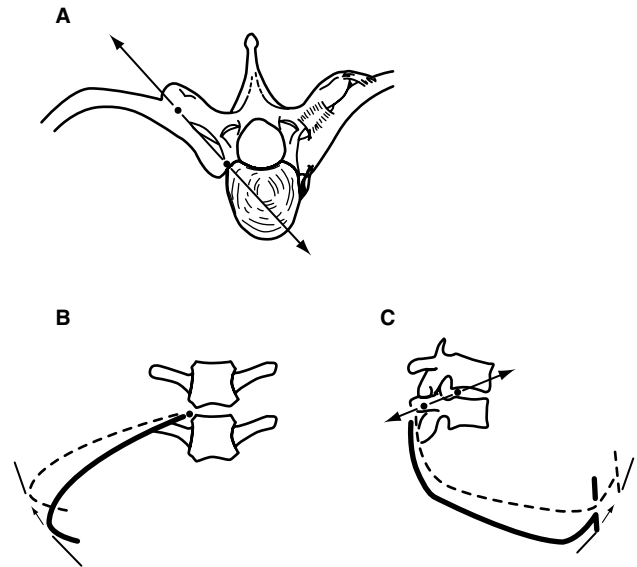


FIGURE 22-2 Respiratory displacements of the rib cage. A, Diagram of a typical thoracic vertebra and a pair of ribs (viewed from above). Each rib articulates with both the body and the transverse process of the vertebra (closed circles) and is bound to it by strong ligaments (right). The motion of the rib, therefore, occurs primarily through a rotation around the axis defined by these articulations (solid line and double arrowhead). From these articulations, however, the rib slopes caudally and ventrally (B, C). As a result, when it becomes more horizontal in inspiration (dotted line), it causes an increase in both the transverse (B) and the anteroposterior (C) diameter of the rib cage (small arrows). Reproduced with permission from De Troyer A. Respiratory muscle function. In: Shoemaker WC, Ayres SM, Grenvik A, Holbrook PR, editors. Textbook of critical care. Philadelphia: WB Saunders; 2000. p. 1172–84.

In addition, because the muscle fibers of the costal diaphragm insert onto the upper margins of the lower six ribs, they also apply a force on these ribs when they contract, and the cranial orientation of these fibers is such that this force is directed cranially. It therefore has the effect of lifting the ribs and rotating them outward (Figure 22-3). The fall in pleural pressure and the rise in abdominal pressure that result from diaphragmatic contraction, however, act simultaneously on the rib cage, which probably explains why the action of the diaphragm on the rib cage has been controversial for so long.

ACTION OF THE DIAPHRAGM ON THE RIB CAGE

When the diaphragm in anesthetized dogs is activated selectively by electrical stimulation of the phrenic nerves, the upper ribs move caudally, and the cross-sectional area of the upper portion of the rib cage decreases.³ In contrast, the cross-sectional area of the lower portion of the rib cage increases. If a bilateral pneumothorax is subsequently introduced, so that the fall in pleural pressure is eliminated, isolated contraction of the diaphragm causes a greater expansion of the lower rib cage, but the dimensions of the upper rib cage now remain unchanged.³ Thus, the diaphragm contracting alone in the dog has two opposing effects on the rib cage. On the one hand, it has an expiratory action on the upper rib cage,

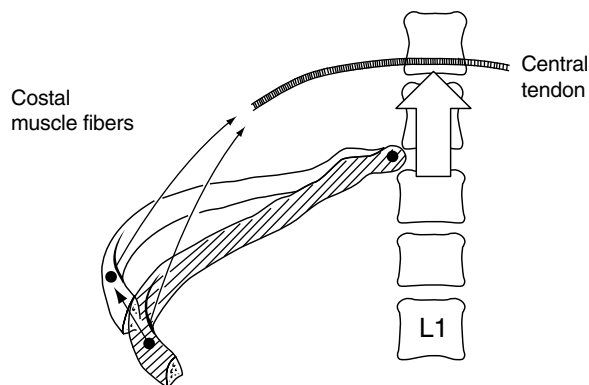


FIGURE 22-3 Insertional component of diaphragmatic action. During inspiration, as the fibers of the costal diaphragm contract, they exert a force on the lower ribs (*arrow*). If the abdominal visceral mass effectively opposes the descent of the diaphragmatic dome (*open arrow*), this force is oriented cranially. Consequently, the lower ribs are lifted and rotate outward. Reproduced with permission from De Troyer A. *Mechanics of the chest wall muscles*. In: Miller AD, Bishop B, Bianchi AL, editors. *Neural control of the respiratory muscles*. Boca Raton (FL): CRC Press; 1996. p. 59–73.

and the fact that this action is abolished by a pneumothorax indicates that it is exclusively the result of the fall in pleural pressure. On the other hand, the diaphragm also has an inspiratory action on the lower rib cage. Although the cross-sectional shape of the rib cage in humans differs from that in the dog, measurements of thoracoabdominal motion during phrenic nerve pacing in subjects with transection of the upper cervical cord^{4,5} and during spontaneous breathing in subjects with traumatic transection of the lower cervical cord^{6,7} have established that the diaphragm contracting alone in humans also has both an expiratory action on the upper rib cage and an inspiratory action on the lower rib cage; this inspiratory action is such that the lower rib cage expands more along its transverse diameter than along its anteroposterior diameter.⁷

Experimental and theoretical studies have confirmed that the inspiratory action of the diaphragm on the lower rib cage results, in part, from the force that the muscle applies on the ribs by way of its insertions; this force is conventionally referred to as the “insertional” force.^{8,9} Indeed, the crural portion of the diaphragm has no direct attachments to the ribs, and its selective stimulation in dogs induces a smaller expansion of the lower rib cage than does stimulation of the costal portion.⁸ The inspiratory action of the diaphragm on the lower rib cage, however, is also related to the existence of the zone of apposition (see Figure 22-1). This zone makes the lower rib cage, in effect, part of the abdominal container, and measurements in dogs have established that, during breathing, the changes in pressure in the pleural recess between the apposed diaphragm and the rib cage are almost equal to the changes in abdominal pressure.¹⁰ Pressure in this pleural recess rises, rather than falls, during inspiration, thus indicating that the rise in abdominal pressure is truly transmitted through the apposed diaphragm to expand the lower rib cage. The force thus developed by the diaphragm on the lower rib cage through the rise in abdominal pressure has been called the “appositional” force,^{8,9} and its magnitude depends, in part, on the

size of the zone of apposition. The greater area of apposed diaphragm at the sides of the rib cage compared with the front presumably accounts for the fact that isolated contraction of the diaphragm in humans distorts the lower rib cage to a more elliptical shape.⁷

It should be appreciated, however, that the insertional and appositional forces are largely determined by the resistance provided by the abdominal contents to diaphragmatic descent. If this resistance is high (ie, if abdominal compliance is low), the dome of the diaphragm descends less, the zone of apposition remains significant throughout inspiration, and the rise in abdominal pressure is greater. Therefore, for a given diaphragmatic activation, the appositional force is increased. A dramatic illustration of this phenomenon is provided by quadriplegic subjects given an external abdominal compression; in such subjects, when passive mechanical support to the abdomen is provided by a pneumatic cuff or an elastic binder, the expansion of the lower rib cage during inspiration is accentuated.^{4,5} Conversely, if the resistance provided by the abdominal contents is small (ie, if the abdomen is very compliant), the dome of the diaphragm descends more easily, the zone of apposition decreases more, and the rise in abdominal pressure is smaller. Consequently, the inspiratory action of the diaphragm on the rib cage is decreased. Should the resistance provided by the abdominal contents be eliminated, the zone of apposition would disappear in the course of inspiration, but, in addition, the contracting diaphragmatic muscle fibers would become oriented transversely inward at their insertions onto the ribs, such that the insertional force would have an expiratory, rather than an inspiratory, action on the lower rib cage. Indeed, when a dog is eviscerated, the diaphragm causes a decrease, rather than an increase, in lower rib cage dimensions.^{3,8}

INFLUENCE OF LUNG VOLUME

The balance between pleural pressure and the insertional and appositional forces of the diaphragm is markedly affected by changes in lung volume. As lung volume decreases from functional residual capacity (FRC) to residual volume (RV), the zone of apposition increases⁹ and the fraction of the rib cage exposed to pleural pressure decreases. As a result, the appositional force increases while the effect of pleural pressure diminishes, and hence the inspiratory action of the diaphragm on the rib cage is enhanced. Conversely, as lung volume increases above FRC, the zone of apposition decreases and a larger fraction of the rib cage becomes exposed to pleural pressure. The inspiratory action of the diaphragm on the rib cage is therefore diminished.^{3,8,9} When lung volume approaches total lung capacity (TLC), the zone of apposition all but disappears, and the diaphragmatic muscle fibers become oriented transversely inward as well as cranially. As in the eviscerated animal, the insertional force of the diaphragm is then expiratory, rather than inspiratory, in direction. These two effects of increasing lung volume account for the inspiratory decrease in the transverse diameter of the lower rib cage that is commonly observed in subjects with emphysema and severe hyperinflation (Hoover’s sign).

Changes in lung volume affect not only the action of the diaphragm on the rib cage but also its inspiratory effect on the lung. When lung volume in supine dogs, cats, and rabbits is passively increased from FRC to TLC, the fall in pleural pressure induced by selective stimulation of the phrenic nerves decreases gradually and continuously.¹¹⁻¹⁴ At TLC, in fact, the pressure fall is almost abolished, and when the respiratory system in these animals is inflated to a lung volume greater than ~104% TLC, the pressure fall is even reversed to become a pressure rise.^{11,14} Such an expiratory action of the diaphragm on the lung has not been observed in humans, but studies in subjects with transection of the upper cervical cord and phrenic nerve pacing,⁴ as well as phrenic nerve stimulation experiments in normal subjects,¹⁵ have shown a similar decline in the lung-inflating action of the human diaphragm with increasing lung volume. As in animals, the diaphragm in humans virtually ceases to generate an inspiratory pressure at TLC.

The adverse effect of hyperinflation on the pressure-generating ability of the diaphragm is primarily related to the decrease in muscle length. Indeed, when lung volume in animals and in humans is increased from RV to TLC, the diaphragmatic muscle fibers shorten by 30 to 40%. In accordance with the length-tension characteristics of the muscle, the force exerted in response to a given stimulation thus decreases markedly. On the other hand, the shape of the diaphragm silhouette hardly changes over the range of a normal vital capacity,^{16,17} and as Smith and Bellemare¹⁵ have pointed out, the relationship between lung volume and the pressure across the diaphragm (transdiaphragmatic pressure, P_{di}) obtained during bilateral stimulation of the phrenic nerves in humans is very similar to the length-tension relationship of diaphragmatic muscle fibers *in vitro*; if an increase in the radius of curvature (flattening of the diaphragm) contributed to the decrease in P_{di} at high lung volumes (Laplace's equation), the decrease in P_{di} should be greater than anticipated on the basis of the decrease in muscle length alone. At very high lung volumes in animals, however, the dome of the diaphragm does become excessively flattened, such that the muscle can no longer expand the abdomen when it contracts. The constriction of the entire rib cage that the contracting diaphragm induces at such lung volumes presumably accounts for the lung-deflating action of the muscle.

INFLUENCE OF POSTURE

Because of the effect of gravity on the abdominal contents and abdominal wall, a change from the seated to the supine posture in humans is associated with a marked increase in abdominal compliance.¹⁸ Consequently, the resistance provided by the abdominal contents to diaphragmatic descent is less effective in this posture, and the two forces developed by the diaphragm to expand the lower rib cage are reduced. Thus, whereas the contracting diaphragm in seated quadriplegic subjects causes an increase in the anteroposterior diameter of the lower rib cage, in the supine posture it produces a decrease in this diameter.⁴⁻⁷ The increase in the transverse diameter of the lower rib cage is also less in this posture.

With a change from the seated to the supine posture, the action of gravity on the abdominal contents also induces a reduction in FRC and a lengthening of the diaphragmatic muscle fibers. Although the concomitant increase in abdominal compliance should cause these fibers to shorten more for a given activation, the force generated by the contracting diaphragm might therefore increase. Studies in patients with transection of the upper cervical cord, in whom bilateral pacing of the phrenic nerves allows the degree of diaphragmatic activation to be maintained constant, have confirmed the influence of posture on the lung-expanding action of the diaphragm.^{4,5} When the patients were supine, the unassisted paced diaphragm was able to generate an adequate tidal volume. However, when the patients were gradually tilted head-up, the change in airway pressure and the tidal volume produced by pacing were progressively and markedly reduced.

INTERACTION BETWEEN THE LEFT AND RIGHT HEMIDIAPHRAGMS

Both in the dog and in humans, each phrenic nerve supplies its own hemidiaphragm, including all the fibers in the crural segment on its own side of the esophageal hiatus. However, when the left and right phrenic nerves in the dog are stimulated simultaneously at a frequency of 10 Hz, the fall in pleural pressure is 10% greater than the sum of the pressure falls obtained during separate left and right stimulation.¹⁹ The difference between the pressure change produced by the canine left and right hemidiaphragms contracting simultaneously and the sum of the individual pressures, in fact, increases gradually to 40 to 50% as the stimulation frequency increases to 35 to 50 Hz.^{14,19} In humans, the change in P_{di} obtained during simultaneous stimulation of the left and right phrenic nerves with single twitches is similarly greater than the sum of the P_{di} values obtained during separate left and right stimulation.²⁰ Thus, the left and right hemidiaphragms have a synergistic interaction on the lung, and this implies that the pressure loss induced by hemidiaphragmatic paralysis is greater than anticipated on the basis of the pressure generated by one hemidiaphragm alone. The frequency dependence of the synergism further implies that this additional pressure loss should be particularly prominent when an increase in respiratory neural drive is needed, such as during exercise.

This peculiar interaction results, in part, from the fact that the diaphragmatic muscle fibers shorten more during unilateral contraction than during bilateral contraction.¹⁹ Consequently, the force exerted during contraction is smaller in the first instance than in the second. However, the main determinant of this interaction is related to the configuration of the muscle. That is, during unilateral diaphragmatic contraction, the inactive hemidiaphragm is stretched and develops passive tension, which reduces the caudal displacement of the central portion of the dome and impedes the descent of the contracting hemidiaphragm. As a result, the volume displaced (and the pressure generated) by this particular hemidiaphragm is reduced relative to the volume that it displaces when the contralateral hemidiaphragm contracts simultaneously.¹⁹

INTERCOSTAL MUSCLES

FUNCTIONAL ANATOMY

The intercostal muscles are two thin muscle layers occupying each of the intercostal spaces. The external intercostal muscles extend from the tubercles of the ribs dorsally to the costochondral junctions ventrally, with their fibers oriented obliquely caudad and ventrally from the rib above to the rib below. In contrast, the internal intercostal muscles extend from the angles of the ribs dorsally to the sternocostal junctions ventrally, with their fibers running caudad and dorsally from the rib above to the rib below. Thus, although the intercostal spaces contain two layers of intercostal muscle in their lateral portion, they contain a single layer in their ventral and dorsal portions. Ventrally, between the sternum and the chondrocostal junctions, the only fibers are those of the internal intercostal muscles; because of its location and particular function (see below), this portion of the internal intercostal muscles is usually called the “parasternal intercostal muscles.” Dorsally, from the angles of the ribs to the vertebrae, the only fibers come from the external intercostal muscles. These latter, however, are duplicated in each interspace by a thin, spindle-shaped muscle that runs from the tip of the transverse process of the vertebra cranially to the angle of the rib caudally; this muscle is the “levator costae.” All intercostal muscles are innervated by the intercostal nerves.

ACTIONS OF INTERCOSTAL MUSCLES ON THE RIBS AND THE LUNG

The actions of the intercostal muscles have conventionally been regarded according to the theory proposed by Hamberger,²¹ as shown in Figure 22-4. When an intercostal muscle contracts in one interspace, it pulls the upper rib down and the lower rib up. However, as the fibers of the external intercostal muscle slope caudad and ventrally from the rib above to the rib below, their lower insertion is more distant from the center of rotation of the ribs (ie, the costovertebral articulations) than their upper insertion. Consequently, when this muscle contracts, the torque acting on the lower rib is greater than that acting on the upper rib, so its net effect would be to raise the ribs and to inflate the lung. In contrast, as the fibers of the internal intercostal muscle slope caudad and dorsally from the rib above to the rib below, their lower insertion is less distant from the center of rotation of the ribs than the upper one. As a result, when this muscle contracts, the torque acting on the lower rib is smaller than that acting on the upper rib, so its net effect would be to lower the ribs and to deflate the lung. Hamberger further concluded that the action of the parasternal intercostal muscles should be referred to the sternum rather than to the spine; although these muscles form part of the internal intercostal layer, their contraction would therefore raise the ribs and inflate the lung.

In agreement with this theory, selective activation of the canine parasternal intercostal muscles by electrical stimulation elicits a large cranial displacement of the ribs and an increase in lung volume.^{22,23} Measurements of the respiratory displacements of the costal cartilages and the sternum

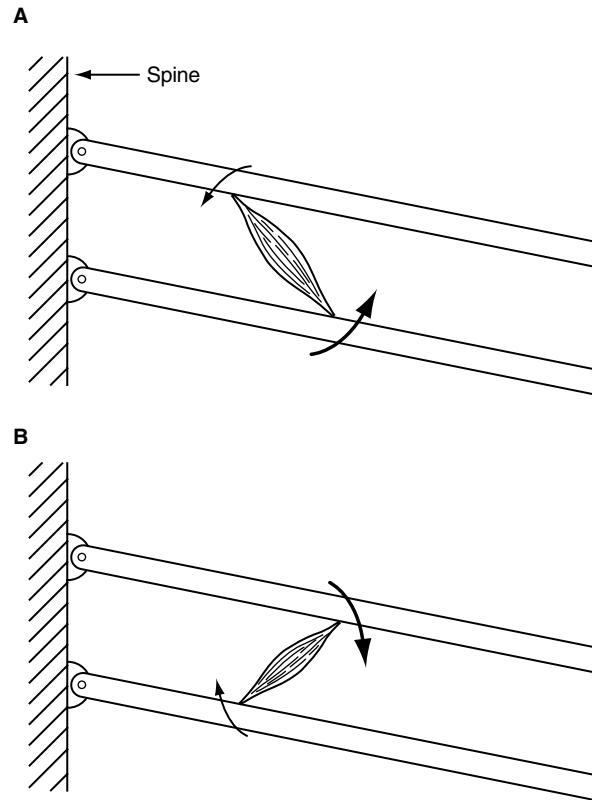


FIGURE 22-4 Diagram illustrating the actions of the intercostal muscles, as proposed by Hamberger.²¹ The hatched area in each panel represents the spine, and the two bars oriented obliquely represent two adjacent ribs; these are linked to each other by the sternum (right). The external (A) and internal interosseous (B) intercostal muscles are depicted as single bundles, and the torques acting on the ribs during contraction of these muscles are represented by arrows. See text for further explanation.

in normal subjects have indicated that the human parasternal intercostal muscles, particularly those situated in the second and third interspaces, also have an inspiratory effect on the lung.²⁴ However, when either the external or the internal interosseous intercostal muscle in a single interspace is selectively stimulated at FRC in the dog, both ribs move closer together, but the cranial displacement of the rib below is always greater than the caudal displacement of the rib above.^{25,26} More importantly, both in the dog²⁷ and in humans,²⁸ the external and internal interosseous intercostal muscles show marked topographic differences in their actions on the lung. Specifically, in the dog, the external intercostal muscles in the dorsal portion of the upper interspaces have a significant inspiratory effect, but this effect decreases rapidly both toward the costochondral junctions and toward the base of the rib cage (Figure 22-5). As a result, the external intercostal muscles in the ventral portion of the lower interspaces have an expiratory, rather than an inspiratory, effect. The canine internal interosseous intercostal muscles in the dorsal portion of the lower interspaces have a large expiratory effect, but this effect decreases ventrally and cranially, such that, in the ventral half of the first and second interspaces, it is reversed into an inspiratory effect. The respiratory effects of the external and internal

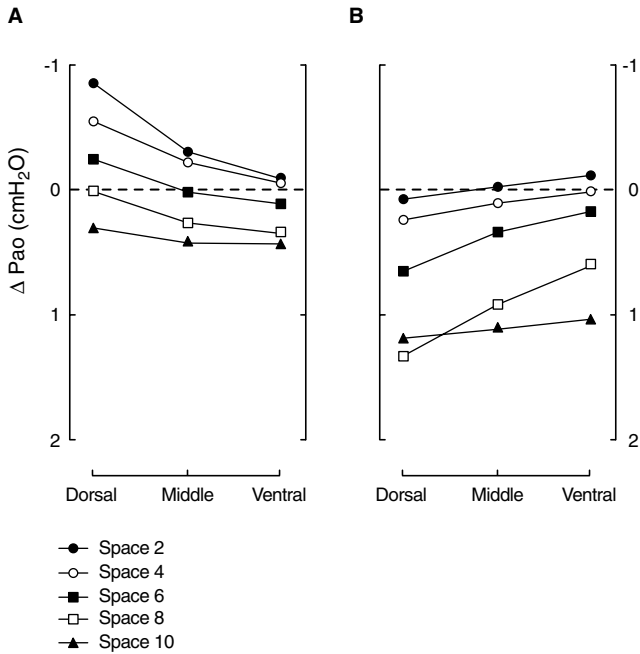


FIGURE 22-5 Actions of the canine external (A) and internal interosseous (B) intercostal muscles on the lung. These data are the maximal changes in airway pressure (ΔP_{ao}) that the muscles in the dorsal, middle, and ventral portions of the second, fourth, sixth, eighth, and tenth interspaces can generate when contracting against a closed airway. A negative ΔP_{ao} indicates an inspiratory effect, whereas a positive ΔP_{ao} indicates an expiratory effect. Reproduced with permission from De Troyer A et al.²⁷

intercostal muscles in humans show qualitatively similar topographic distributions,²⁸ although the expiratory effect of the human internal intercostal muscles is greatest in the ventral, rather than the dorsal, portion of the lower interspaces.

The theory of Hamberger cannot explain such dorsoventral and rostrocaudal gradients, and this is because it is based on a two-dimensional model of the rib cage. Indeed, the model is planar, and the ribs are modeled as straight bars rotating around axes that lie perpendicular to the plane of the ribs (see Figure 22-4). Also, the theory of Hamberger contains the implicit assumptions that all the ribs have equal compliances and are equally coupled to the lung.

Real ribs are curved, however, and this curvature has critical effects on the moments exerted by the intercostal muscles,^{27,29} as shown in Figure 22-6A. Because the axis of rib rotation is oriented dorsally and laterally, at point “a” on the rib, the tangent plane of the rib cage is perpendicular to the axis of rotation. For the external intercostal muscle, therefore, the distance between the point of attachment of the muscle on the lower rib and the axis of rotation is greater than the distance between the point of attachment of the muscle on the upper rib and the axis of rotation. Consequently, at point “a,” the moment exerted by the muscle on the lower rib is greater than the moment exerted on the upper rib, and the net moment is inspiratory. However, at point “b,” the tangent plane of the rib cage lies parallel to the axis of rib rotation, so the distances between the points of attachment of the muscle on the two ribs and the axes of

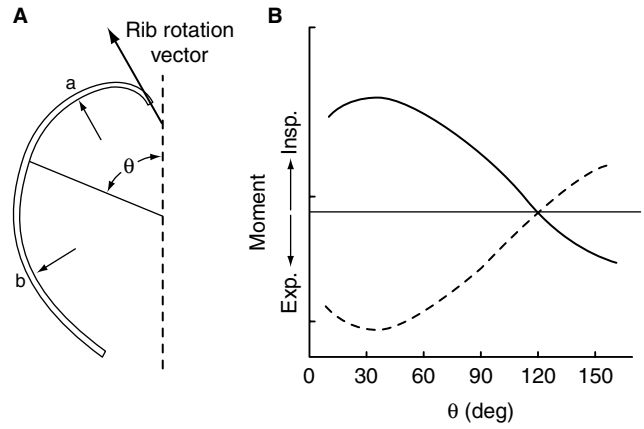


FIGURE 22-6 Effects of rib curvature on the net moment exerted by an intercostal muscle. The plan form of a typical rib in the dog and its axis of rotation (bold vector) are shown in (A). At point “a,” the distances between the points of attachment of an intercostal muscle on the lower and upper ribs and the axes of rotation of the ribs are different, and the muscle exerts a net moment on the ribs. At point “b,” however, the distances between the points of attachment of an intercostal muscle on the lower and upper ribs and the axes of rotation of the ribs are equal, and the muscle exerts no net moment. Thus, the net moment exerted by the muscle depends on the angular position (θ) around the rib, as shown in B. The external intercostal muscle (continuous line) has the greatest inspiratory moment in the dorsal portion of the rib cage (θ between 15° and 60°); this inspiratory moment then decreases as one moves around the rib cage (θ between 60° and 120°) and is reversed into an expiratory moment in the vicinity of the costochondral junction (θ greater than 120°). The internal intercostal muscle (dashed line) shows a similar gradient in expiratory moment.

rib rotation are equal, and the net moment exerted by the muscle is zero. Thus, the net inspiratory moment of the external intercostal muscle is maximal in the dorsal region of the rib cage, decreases to zero at point “b,” and is reversed to an expiratory moment in the ventral region of the rib cage (Figure 22-6B). The net expiratory moment of the internal intercostal muscle is similarly maximal in the dorsal region, decreases in magnitude as one moves away from the spine, and becomes an inspiratory moment in the vicinity of the sternum (Figure 22-6B). Although the difference between the expiratory effect of the internal interosseous intercostal muscles in the dorsal region of the rib cage and the inspiratory effect of the parasternal intercostal muscles was already inferred by Hamberger, it was not appreciated that the differences between the actions of the muscles in the dorsal and ventral regions are the result of gradual transitions, not abrupt changes of mechanism at the costochondral junctions.

In addition, in contrast to the model of Hamberger, the radii of curvature of the ribs increase from the top to the base of the rib cage, the rotational compliances of the different ribs are different,^{23,28} and the coupling of the different ribs to the lung varies from the top to the base of the rib cage as well.³⁰ Specifically, in the dog at FRC, the change in lung volume produced by a given rib displacement increases gradually with increasing rib number in the upper half of the cage, whereas in the lower half of the cage, the change in lung volume produced by a given rib displacement decreases

rapidly with increasing rib number. As a result of these topographic differences in rib compliance and rib–lung coupling, both the external and internal interosseous intercostal muscles in the upper interspaces tend to have an inspiratory effect on the lung. In contrast, in the lower interspaces, both intercostal muscles tend to have an expiratory effect.³⁰ As shown in Figure 22-5, the location of the muscles along the rostrocaudal axis of the rib cage is the single most important determinant of their respiratory effects, and the orientation of the muscle fibers primarily operates to modulate these effects. That is, for a given muscle mass, the external intercostal muscle in an upper interspace has a larger inspiratory effect on the lung than the internal intercostal muscle, and the external intercostal muscle in a lower interspace has a smaller expiratory effect than the internal intercostal muscle.³⁰

RESPIRATORY FUNCTION OF INTERCOSTAL MUSCLES

These topographic differences in respiratory effects imply that the actions of the muscles on the lung during breathing are largely determined by the topographic distribution of neural drive. Electromyographic studies in dogs,²² cats,^{31,32} baboons,³³ and humans^{34–36} have clearly established that the parasternal intercostal muscles invariably contract during the inspiratory phase of the breathing cycle. These muscles, therefore, have a definite inspiratory action on the lung during breathing. Similarly, the external intercostal muscles in animals and in humans are active only during inspiration.^{31–34,37,38} However, external intercostal muscle inspiratory activity is found exclusively in the muscle areas with an inspiratory mechanical advantage, and the topographic distribution of this activity is closely matched with the topographic distribution of inspiratory effect.^{37–39} Both in the dog and in humans, inspiratory activity in the external intercostal muscles is thus greatest in the dorsal portion of the upper interspaces, that is, in the areas where the muscles have the greatest inspiratory effect. Inspiratory activity then declines gradually in the caudal and the ventral directions, as does the inspiratory effect. The external intercostal muscles with an expiratory effect, that is, in the ventral portion of the lower interspaces, are never active during breathing, including when the demand placed on the respiratory muscle pump is increased by carbon dioxide–enriched gas mixtures or by external mechanical loads.³⁸ This distribution of neural drive confers to the external intercostal muscles an inspiratory action on the lung during breathing.

On the other hand, the internal interosseous intercostal muscles are active only during expiration, and the topographic distribution of expiratory activity in these muscles mirrors the topographic distribution of expiratory effect. In the dog, internal intercostal muscle expiratory activity is thus greatest in the dorsal portion of the lower interspaces and decreases progressively in the cranial and ventral directions.³⁸ The areas of internal interosseous intercostal muscle with an inspiratory effect, that is, in the ventral portion of the upper interspaces, are never active during breathing. This distribution of neural drive must confer on the internal interosseous intercostal muscles an expiratory action on the lung during breathing. Thus, the external and internal interosseous intercostal muscles do have opposite actions on

the lung during breathing, as conventionally thought, but it must be appreciated that these opposite actions are primarily the result of selective regional activation of the muscles rather than the orientations of the muscle fibers.

Although the external intercostal muscles (including the levator costae) in the upper interspaces and the parasternal intercostal muscles contract together during inspiration, several observations indicate that in anesthetized animals these two muscle groups contribute differently to the cranial displacement of the ribs and the expansion of the lung. First, in anesthetized dogs and cats, the inspiratory cranial displacement of the ribs occurs together with a caudal displacement of the sternum, and this results from the action of the parasternal intercostal muscles.^{22,40,41} Indeed, isolated contraction of these muscles causes the sternum to move caudally,²² whereas isolated contraction of the external intercostal muscles displaces the sternum cranially.^{41,42} Second, when the parasternal intercostal muscle in a single interspace is selectively denervated in supine dogs⁴³ and in upright baboons,³³ the normal inspiratory shortening of the muscle is virtually abolished. Third, when the canine parasternal intercostal muscles in all interspaces are denervated, there is a compensatory increase in external intercostal muscle inspiratory activity, yet the inspiratory cranial displacement of the ribs is markedly reduced.⁴⁴ Denervation of the parasternal intercostal muscles in all interspaces in dogs with diaphragmatic paralysis also elicits a large decrease in tidal volume.⁴¹ In contrast, when the canine external intercostal muscles in all interspaces are severed and the parasternal intercostal muscles are left intact, the inspiratory cranial displacement of the ribs and tidal volume show only moderate reductions, although parasternal muscle inspiratory activity remains unchanged.^{41,44} In anesthetized animals, therefore, the contribution of the parasternal intercostal muscles to resting breathing is much greater than that of the external intercostal muscles.

However, whereas the parasternal intercostal muscles in the dog are thicker than the external intercostal muscles, in humans the external intercostal muscles are thicker, and the total mass of external intercostal muscle is about six times greater than the parasternal intercostal muscle mass.²⁸ As a result, the potential inspiratory effect of the external intercostal muscles in humans is about five times greater.²⁸ In addition, the results of recent electromyographic studies have shown that during resting breathing in normal subjects, the external intercostal muscle in the dorsal portion of the third interspace and the parasternal intercostal muscle in the same interspace start firing simultaneously at the onset of inspiration, but the external intercostal muscle motor units fire with greater discharge rates at the peak of inspiration.³⁹ This suggests that, in humans, the dorsal areas of the external intercostal muscle receive greater neural drive than the parasternal intercostal muscles and make a greater contribution to lung inflation.

INFLUENCE OF LUNG VOLUME

In the dog, the length–tension relationship of the parasternal and external intercostal muscles is contracted on its length axis compared with that of the diaphragm.⁴⁵

Therefore, if the parasternal intercostal and external intercostal muscles in the upper interspaces shortened as much as the diaphragm during passive inflation above FRC, their force-generating ability would decrease more. However, whereas the diaphragm shortens by 30 to 40% during inflation from FRC to TLC, the parasternal and upper external intercostal muscles shorten by only ~10%.^{23,27} In addition, whereas the resting FRC length of the diaphragm in supine dogs is close to or a little shorter than the muscle optimal length (L_0),^{46,47} the canine parasternal intercostal muscles at FRC are 10 to 15% longer than L_0 .⁴⁵ Consequently, increasing lung volume above FRC causes the diaphragm and the upper external intercostal muscles to move away from L_0 but causes the parasternal intercostal muscles to move toward L_0 . The net result of these changes is that the force-generating ability of the upper external intercostal muscles should diminish as volume is increased from FRC to TLC; in contrast, the force-generating ability of the canine parasternal intercostal muscles remains unchanged or slightly increases.^{48,49}

The fall in pleural pressure produced by the contracting parasternal and external intercostal muscles, however, is determined by the interaction between the force developed by the muscles and the ability of the ribs to move cranially and outward. In the dog, the impedance of the ribs to cranial displacement increases as lung volume is increased above FRC.²⁵ Moreover, as the ribs become more horizontal with inflation, one would expect that a given cranial rib displacement would lead to a smaller outward displacement. Such alterations in rib displacement should add to the length–tension characteristics of the muscles to reduce the lung-expanding action of the external intercostal muscles at high lung volumes; they might reduce the lung-expanding action of the parasternal intercostal muscles as well, even though the force developed by them might be greater than at FRC. Indeed, DiMarco and colleagues⁵⁰ have shown in dogs that the fall in pleural pressure induced by tetanic, simultaneous stimulation of the parasternal and interosseous (external and internal) intercostal muscles in the upper six or seven interspaces decreases gradually as lung volume is increased above FRC. Thus, the change in pressure obtained during stimulation at TLC was ~30% of the change obtained during stimulation at FRC, and similar observations were made during isolated stimulation of the interosseous intercostal muscles.⁵⁰ Ninane and Gorini⁵¹ also observed that the fall in pleural pressure produced by selective contraction of the canine parasternal intercostal muscles decreases progressively as lung volume is increased above FRC. The effect of lung volume on the human intercostal muscles, however, is unknown.

NONRESPIRATORY FUNCTION OF INTERCOSTAL MUSCLES

The insertions and orientations of the external and internal intercostal muscles suggest that these muscles would also be able to twist the rib cage (Figure 22-7). Thus, contraction of the external intercostal muscles on one side of the sternum would rotate the ribs in a transverse plane, so that the upper ribs would move ventrally whereas the lower ribs would move dorsally. In contrast, contraction of the internal intercostal

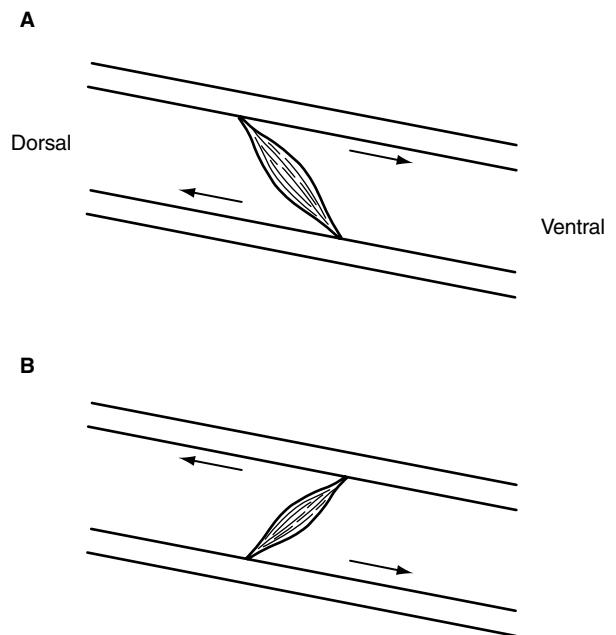


FIGURE 22-7 Diagram of an intercostal space on the right side of the chest (lateral view), illustrating the actions of the external (A) and internal interosseous (B) intercostal muscles during rotations of the trunk. As in Figure 22-4, the two bars oriented obliquely represent two adjacent ribs, and the muscles are depicted as single bundles. The *arrows* indicate the component of tension vector acting along the ribs. Adapted from De Troyer A. Mechanics of the chest wall muscles. In: Miller AD, Bishop B, Bianchi AL, editors. Neural control of the respiratory muscles. Boca Raton (FL): CRC Press; 1996. p. 59–73.

muscles on one side of the sternum would move the upper ribs dorsally and the lower ribs ventrally. In agreement with this idea, Decramer and colleagues⁵² have found in anesthetized dogs that the external and internal interosseous intercostal muscles show large, reciprocal changes in length during passive rotations of the thorax. When the animal's trunk was twisted to the left, the external intercostal muscles on the right side and the internal interosseous intercostal muscles on the left side shortened. At the same time, the external intercostal muscles on the left side and the internal intercostal muscles on the right side lengthened. The opposite pattern was seen when the animal's trunk was twisted to the right, with a marked shortening of the right internal and left external intercostal muscles and a lengthening of the left internal muscles and right external muscles. Thus, the length of these muscles changed in the way expected if they were producing the rotations, and indeed, electromyographic studies in normal humans have shown that the external intercostal muscles on the right side of the chest are activated when the trunk is rotated to the left, whereas they remain silent when the trunk is rotated to the right⁵³; conversely, the internal intercostal muscles on the right side contracted only when the trunk was rotated to the right.

TRIANGULARIS STERNI

The triangularis sterni, also called the transversus thoracis, is not conventionally included among the intercostal muscles. However, this muscle lies deep to the parasternal

intercostal muscles, and its fibers are nearly perpendicular to the latter, running from the dorsal aspect of the caudal half of the sternum to the inner surface of the costal cartilages of the third to seventh ribs. In contrast to the parasternal intercostal muscles, therefore, its selective stimulation in the dog induces a large caudal displacement of the ribs with a small cranial displacement of the sternum and a decrease in lung volume.⁵⁴ The triangularis sterni also receives its motor supply from the intercostal nerves.

In quadrupeds, the triangularis sterni invariably contracts during the expiratory phase of the breathing cycle.⁵⁴⁻⁵⁶ In so doing, it pulls the ribs caudally and deflates the rib cage below its neutral (resting) position.⁵⁴ Consequently, when the muscle relaxes at the end of expiration, there is a passive rib cage expansion and an increase in lung volume that precedes the onset of inspiratory muscle contraction. In these animals, the triangularis sterni thus shares the work of breathing with the inspiratory muscles and helps the parasternal and upper external intercostal muscles produce the rhythmic inspiratory expansion of the rib cage.⁵⁴ In humans, however, the muscle is thin and usually inactive during resting breathing.⁵⁷ Therefore, even though it contracts during expiratory efforts such as coughing, laughing, and speech,⁵⁷ its expiratory effect on the lung is small compared with that of the internal intercostal muscles.^{24,28}

MUSCLES OF THE NECK

SCALENE MUSCLES

The scalene muscles in humans comprise three muscle heads that run from the transverse processes of the lower five cervical vertebrae to the upper surfaces of the first two ribs. Although they have traditionally been considered to be “accessory” muscles of inspiration, electromyographic studies with concentric needle electrodes have established that, in normal humans, these muscles invariably contract during inspiration, including when the increase in lung volume is very small.^{35,36,58,59}

When the scalene muscles are selectively activated by electrical stimulation in the dog, they produce a large cranial displacement of the ribs and sternum, an increase in rib cage anteroposterior diameter, and an increase in lung volume.⁶⁰ Since there is no clinical setting that causes paralysis of all the inspiratory muscles without also affecting the scalene muscles, the isolated action of these muscles on the human rib cage cannot be defined precisely. Two observations, however, indicate that contraction of the scalene muscles is an important determinant of the expansion of the upper rib cage during breathing. First, when normal subjects attempt to inspire with the diaphragm alone, there is a marked, selective decrease in scalene muscle activity associated with either less inspiratory increase or a paradoxical decrease in anteroposterior diameter of the upper rib cage.³⁶ Second, the inspiratory inward displacement of the upper rib cage characteristic of quadriplegia is usually not observed when scalene muscle function is preserved after lower cervical cord transection.⁷ As the scalene muscles are innervated from the lower five cervical segments, persistent inspiratory contraction is frequently seen in subjects with a transection

at the C7 level or below. In such subjects, the anteroposterior diameter of the upper rib cage tends to remain constant or to increase slightly during inspiration. The fall in pleural pressure produced by a maximal, isolated contraction of these muscles in normal humans would be similar to that caused by the parasternal intercostal muscles in all interspaces.⁶¹

STERNOCLEIDOMASTOID MUSCLES AND OTHER ACCESSORY MUSCLES OF INSPIRATION

Many additional muscles, such as the pectoralis minor, the trapezius, the erector spinae, the serrati, and the sternocleidomastoid muscles, can elevate the ribs when they contract.

These muscles, however, run between the shoulder girdle and the rib cage, between the spine and the shoulder girdle, or between the head and the rib cage. Therefore, they have primarily postural functions. In healthy individuals, they contract only during increased inspiratory efforts; in contrast to the scalene muscles, therefore, they are true “accessory” muscles of inspiration.

Of all these muscles, only the sternocleidomastoid muscles, which descend from the mastoid process to the ventral surface of the manubrium sterni and the medial third of the clavicle, have been thoroughly studied. The pressure-generating ability of the sternocleidomastoid muscles in normal humans is about the same as that of the scalene muscles,⁶¹ and their action on the rib cage has been inferred from measurements of chest wall motion in subjects with transection of the upper cervical cord. Indeed, in such subjects, the diaphragm, intercostal muscles, scalene muscles, and abdominal muscles are paralyzed, but the sternocleidomastoid muscles (the motor innervation of which largely depends on the eleventh cranial nerve) are spared and contract forcefully during unassisted inspiration.^{4,62} When breathing spontaneously, these subjects show a prominent inspiratory cranial displacement of the sternum and a large inspiratory expansion of the upper rib cage, particularly in its anteroposterior diameter. This prominent cranial displacement of the sternum, however, combined with the fall in intrathoracic pressure, elicits a decrease in the transverse diameter of the lower rib cage^{4,62} (Figure 22-8).

ABDOMINAL MUSCLES

FUNCTIONAL ANATOMY

The four abdominal muscles with significant respiratory function in humans make up the ventrolateral wall of the abdomen. The rectus abdominis muscle is the most ventral of these muscles. It originates from the ventral aspect of the sternum and the fifth, sixth, and seventh costal cartilages and runs caudally along the whole length of the abdominal wall to insert into the pubis. The muscle is enclosed in a sheath formed by the aponeuroses of the three muscles situated laterally. The most superficial of these is the external oblique muscle, which originates by fleshy digitations from the external surface of the lower eight ribs, well above the costal margin, and directly covers the lower ribs and intercostal muscles. Its fibers radiate caudally to the iliac crest and inguinal ligament and medially to the linea alba. The

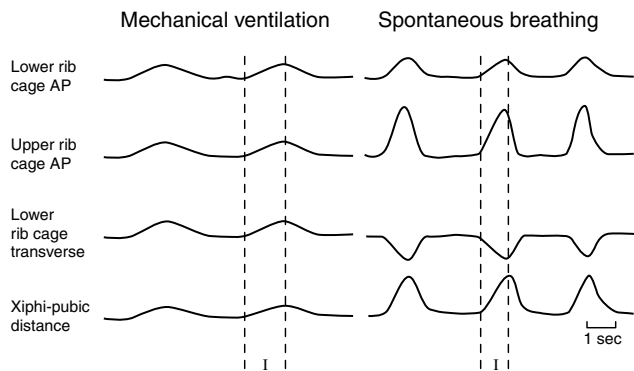


FIGURE 22-8 Pattern of rib cage motion during mechanical ventilation (*left*) and during spontaneous breathing (*right*) in a quadriplegic subject with a traumatic transection of the upper cervical cord (C_1). Each panel shows, from top to bottom, the respiratory changes in anteroposterior (AP) diameter of the lower rib cage, the changes in AP diameter of the upper rib cage, the changes in transverse diameter of the lower rib cage, and the changes in xiphipubic distance. Upward deflections correspond to an increase in diameter or an increase in xiphipubic distance (ie, a cranial displacement of the sternum); I indicates the duration of inspiration. Note that all rib cage diameters and the xiphipubic distance increase in phase during mechanical inflation. During spontaneous inspiration, however, the xiphipubic distance and the upper rib cage AP diameter increase more than the lower rib cage AP diameter, and the lower rib cage transverse diameter decreases.

internal oblique muscle lies deep to the external oblique muscle. Its fibers arise from the iliac crest and inguinal ligament and diverge to insert on the costal margin and an aponeurosis contributing to the rectus sheath down to the pubis. The transversus abdominis muscle is the deepest of the muscles of the lateral abdominal wall. It arises from the inner surface of the lower six ribs, where it interdigitates with the costal insertions of the diaphragm. From this origin, and from the lumbar fascia, the iliac crest, and the inguinal ligament, its fibers run circumferentially around the abdominal visceral mass and terminate ventrally in the rectus sheath.

ACTIONS OF THE ABDOMINAL MUSCLES

These four muscles have important functions as flexors (rectus abdominis muscle) and rotators (external oblique and internal oblique muscles) of the trunk, but as respiratory muscles, they have two main actions. First, as they contract, they pull the abdominal wall inward and produce an increase in abdominal pressure. As a result, there is a cranial motion of the diaphragm into the thoracic cavity, leading to an increase in pleural pressure and a decrease in lung volume. Second, these four muscles displace the rib cage through their insertions on the ribs. These insertions would suggest that the action of all abdominal muscles is to pull the ribs caudally and to deflate the rib cage, another expiratory action. Measurements of rib cage motion during electrical stimulation of the individual muscles in dogs have shown, however, that these muscles also have an inspiratory action on the rib cage.^{63,64} Indeed, the rise in pleural pressure resulting from the cranial displacement of the diaphragm tends to expand the portion of the rib cage apposed to the

lung. Furthermore, by forcing the diaphragm cranially and stretching it, the contracting abdominal muscles induce both an increase in size of the zone of apposition of the diaphragm to the rib cage (see Figure 22-1) and an increase in passive diaphragmatic tension. This passive tension tends to raise the lower ribs and to expand the lower rib cage in the same way as does an active diaphragmatic contraction (“insertional” force).

The action of the abdominal muscles on the rib cage is thus determined by the balance between the insertional, expiratory force of the muscles and the inspiratory force related to the rise in pleural and abdominal pressures. Isolated contraction of the external oblique muscle in humans produces a small caudal displacement of the sternum and a large decrease in the rib cage transverse diameter, but the rectus abdominis muscle, while causing a marked caudal displacement of the sternum and a large decrease in the anteroposterior diameter of the rib cage, also produces a small increase in the rib cage transverse diameter.⁶⁵ The isolated actions of the internal oblique and transversus abdominis muscles on the human rib cage are not known. The anatomic arrangement of the transversus abdominis muscle, however, would suggest that, among the abdominal muscles, this muscle has the smallest insertional, expiratory action on the ribs and the greatest effect on abdominal pressure. Isolated contraction of the transversus abdominis muscle should therefore produce little or no expiratory rib cage displacement.

RESPIRATORY FUNCTION OF THE ABDOMINAL MUSCLES

Irrespective of their actions on the rib cage, the abdominal muscles are primarily expiratory muscles through their action on the diaphragm and the lung, and they play important roles in activities such as coughing and speaking. However, these muscles may also assist inspiration, and the horse breathing at rest provides a dramatic illustration of this inspiratory action.⁶⁶ As shown in Figure 22-9, this animal displays a biphasic airflow pattern during both expiration and inspiration. The first part of expiration results from the relaxation of the inspiratory muscles and is, therefore, essentially passive. As expiration proceeds, however, there is strong contraction of the abdominal muscles, which deflates the respiratory system below its relaxation volume and generates a second peak of expiratory airflow. At the onset of the subsequent inspiration, the abdominal muscles relax. In so doing, they promote passive descent of the diaphragm and induce an increase in lung volume as the respiratory system returns toward its relaxation volume; this phenomenon accounts for the first peak of inspiratory airflow. After inspiratory flow diminishes, the inspiratory muscles contract, producing a second peak of inspiratory flow. Although such a flow pattern is rather characteristic of the horse, dogs use a similar strategy of breathing. When anesthetized dogs are placed in the head-up or the prone posture, relaxation of the abdominal muscles at end-expiration accounts for up to 40 to 60% of tidal volume.^{67,68}

Healthy humans do not use such a breathing strategy at rest. However, phasic expiratory contraction of the abdominal muscles does occur whenever the demand placed on the

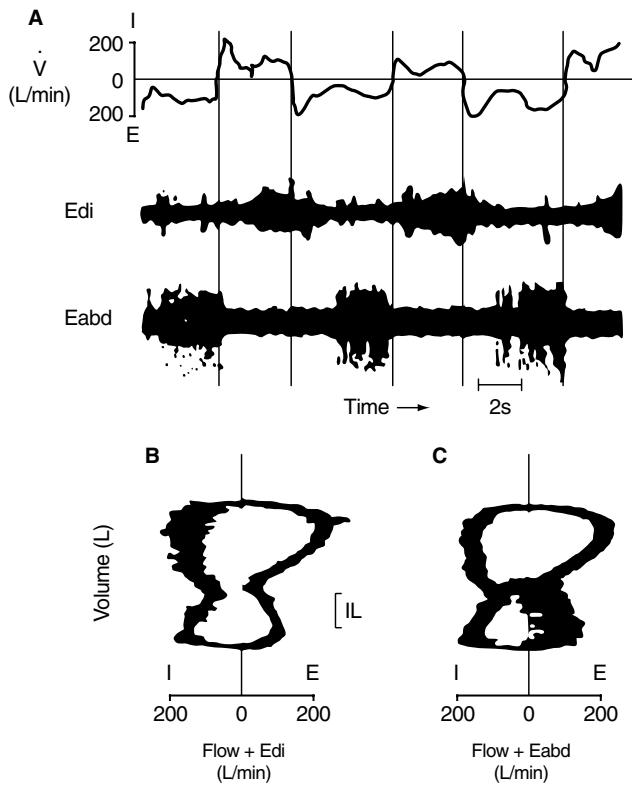


FIGURE 22-9 Strategy of breathing in the horse. A, Traces of air-flow (\dot{V}), electromyogram of the diaphragm (E_{di}), and electromyogram of the abdominal internal oblique muscle (E_{abd}) versus time. Note that the onset of inspiratory flow clearly precedes the onset of E_{di} and that the onset of expiratory flow precedes the onset of E_{abd} . B, The corresponding flow–volume loop, in which the raw E_{di} signal has been electrically added to the flow tracing, also shows that most of the E_{di} signal is in the second phase of inspiration. C, The flow–volume loop with the raw E_{abd} signal electrically added to the flow tracing further shows that the E_{abd} signal is confined to the second phase of expiration. Reproduced with permission from Koterba AM et al.⁶⁶

inspiratory muscles is increased, such as during exercise or during the breathing of carbon dioxide-enriched gas mixtures. It is noteworthy that, in these conditions, the transversus abdominis muscle is recruited well before activity can be recorded from either the rectus abdominis muscle or the external oblique muscle.^{69,70} In view of the actions of these muscles, this preferential recruitment of the transversus abdominis muscle further strengthens the idea that the effect of the abdominal muscles on abdominal pressure is far more important in the act of breathing than is their action on the rib cage.

INFLUENCE OF LUNG VOLUME

Whereas passive inflation causes shortening of the diaphragm and inspiratory intercostal muscles, it induces lengthening of the abdominal muscles, particularly the transversus abdominis and internal oblique muscle. In supine, anesthetized dogs, these two muscles lengthen by 15 to 25% during inflation from FRC to TLC, whereas the rectus abdominis and external oblique muscles lengthen by only 1 to 3%.⁷¹ With passive inflation, therefore, the force

produced by the contracting abdominal muscles increases, and in dogs and rabbits, the rise in abdominal pressure obtained during selective, tetanic stimulation of the muscles at TLC is ~25% greater than the pressure rise obtained for the same stimulation at FRC.⁶⁴ A similar observation has been made during magnetic stimulation of the abdominal muscles in normal humans and in quadriplegic subjects.⁷² In addition, passive inflation induces a decrease in the passive diaphragmatic tension, particularly when the subjects are in the supine posture. As a result, the rise in abdominal pressure generated by the abdominal muscles is better transmitted to the pleural cavity, which further enhances the lung-deflating action of the muscles.⁶⁴

SUMMARY AND CONCLUSIONS

Although the diaphragm is the main respiratory muscle in humans, movement of the chest wall during breathing is an integrated process that involves many muscles. During spontaneous quiet breathing, the parasternal intercostal muscles, the external intercostal muscles in the dorsal portion of the upper interspaces, and the scalene muscles contract in a coordinated manner during inspiration to lift the ribs and expand the upper half of the rib cage. Relaxation of these muscles at end-inspiration allows the respiratory system to return, through its passive elastic properties, to its neutral (resting) position. During exercise, however, as the production of carbon dioxide by the locomotor muscles is augmented, the regulation of chest wall muscle activation becomes even more complex, involving not only increased activation of the muscles already active during resting breathing but also the recruitment of additional muscles that augment chest wall expansion (the so-called “accessory” muscles). In addition, exercise hyperpnea is associated with phasic expiratory contraction of muscles, such as the transversus abdominis muscle, the triangularis sterni muscle, and the internal interosseous intercostal muscles in the lower interspaces, that deflate the abdomen and the rib cage and increase expiratory airflow, so as to bring rhythmically the respiratory system below its resting volume. Although these muscles have an expiratory action on the lungs, their relaxation at end-expiration causes an increase in lung volume; they therefore reduce the load on the inspiratory muscles and help them meet the increased ventilatory requirements.

Breathing is primarily an automatic process, and the pattern of respiratory muscle activation is to a large extent “hard-wired” to the central respiratory controller. Thus, essentially similar adaptations take place when the work of breathing is increased by disease. When some respiratory muscle groups are weak or paralyzed, the remaining muscles have to overcome the entire resistive and elastic load; the strain imposed on them is consequently greater than normal. Similarly, when airflow resistance is abnormally elevated or when dynamic pulmonary and/or chest wall compliance is abnormally reduced, the inspiratory muscles have to generate a greater reduction in pleural pressure to inflate the lungs. The presence of static or dynamic hyperinflation places an additional load on these muscles by making

them operate at shorter than normal lengths and by reducing their ability to lower pleural pressure. When breathing at rest, patients with severe obstructive or restrictive pulmonary impairment will therefore use their muscles in much the same way as normal subjects do during exercise. In such patients, however, as in patients with respiratory muscle paralysis, some of the contracting muscles may have little or no beneficial effect on the act of breathing.

REFERENCES

- Konno K, Mead J. Measurement of the separate volume changes of rib cage and abdomen during breathing. *J Appl Physiol* 1967;22:407–22.
- Mead J. Functional significance of the area of apposition of diaphragm to rib cage. *Am Rev Respir Dis* 1979;119:31–2.
- D'Angelo E, Sant'Ambrogio G. Direct action of contracting diaphragm on the rib cage in rabbits and dogs. *J Appl Physiol* 1974;36:715–9.
- Danon J, Druz WS, Goldberg NB, Sharp JT. Function of the isolated paced diaphragm and the cervical accessory muscles in C₁ quadriplegics. *Am Rev Respir Dis* 1979;119:909–19.
- Strohl KP, Mead J, Banzett RB, et al. Effect of posture on upper and lower rib cage motion and tidal volume during diaphragm pacing. *Am Rev Respir Dis* 1984;130:320–1.
- Mortola JP, Sant'Ambrogio G. Motion of the rib cage and the abdomen in tetraplegic patients. *Clin Sci Mol Med* 1978;54:25–32.
- Estenne M, De Troyer A. Relationship between respiratory muscle electromyogram and rib cage motion in tetraplegia. *Am Rev Respir Dis* 1985;132:53–9.
- De Troyer A, Sampson M, Sigrist S, Macklem PT. Action of costal and crural parts of the diaphragm on the rib cage in dog. *J Appl Physiol* 1982;53:30–9.
- Loring SH, Mead J. Action of the diaphragm on the rib cage inferred from a force–balance analysis. *J Appl Physiol* 1982;53:756–60.
- Urmev WF, De Troyer A, Kelly SB, Loring SH. Pleural pressure increases during inspiration in the zone of apposition of diaphragm to rib cage. *J Appl Physiol* 1988;65:2207–12.
- Sant'Ambrogio G, Saibene F. Contractile properties of the diaphragm in some mammals. *Respir Physiol* 1970;10:349–57.
- Pengelly LD, Alderson AM, Milic-Emili J. Mechanics of the diaphragm. *J Appl Physiol* 1971;30:797–805.
- Kim MJ, Druz WS, Danon J, et al. Mechanics of the canine diaphragm. *J Appl Physiol* 1976;41:369–82.
- Minh VD, Dolan GF, Konopka RF, Moser KM. Effect of hyperinflation on inspiratory function of the diaphragm. *J Appl Physiol* 1976;40:67–73.
- Smith J, Bellemare F. Effect of lung volume on in vivo contraction characteristics of human diaphragm. *J Appl Physiol* 1987;62:1893–900.
- Braun NMT, Arora NS, Rochester DF. Force–length relationship of the normal human diaphragm. *J Appl Physiol* 1982;53:405–12.
- Gauthier AP, Verbanck S, Estenne M, et al. Three dimensional reconstruction of the in vivo human diaphragm shape at different lung volumes. *J Appl Physiol* 1994;76:495–506.
- Estenne M, Yernault JC, De Troyer A. Rib cage and diaphragm–abdomen compliance in humans: effects of age and posture. *J Appl Physiol* 1985;59:1842–8.
- De Troyer A, Cappello M, Meurant N, Scillia P. Synergism between the canine left and right hemidiaphragms. *J Appl Physiol* 2003;94:1757–65.
- Bellemare F, Bigland-Ritchie B, Woods JJ. Contractile properties of the human diaphragm in vivo. *J Appl Physiol* 1986; 61:1153–61.
- Hamberger GE. *De Respirationis Mechanismo et usu genuino*. lena; 1749.
- De Troyer A, Kelly S. Chest wall mechanics in dogs with acute diaphragm paralysis. *J Appl Physiol* 1982;53:373–9.
- De Troyer A, Legrand A, Wilson TA. Rostrocaudal gradient of mechanical advantage in the parasternal intercostal muscles of the dog. *J Physiol (Lond)* 1996;495:239–46.
- De Troyer A, Legrand A, Gevenois PA, Wilson TA. Mechanical advantage of the human parasternal intercostal and triangularis sterni muscles. *J Physiol (Lond)* 1998;513:915–25.
- De Troyer A, Kelly S, Macklem PT, Zin WA. Mechanics of intercostal space and action of external and internal intercostal muscles. *J Clin Invest* 1985;75:850–7.
- Ninane V, Gorini M, Estenne M. Action of intercostal muscles on the lung in dogs. *J Appl Physiol* 1991;70:2388–94.
- De Troyer A, Legrand A, Wilson TA. Respiratory mechanical advantage of the canine external and internal intercostal muscles. *J Physiol (Lond)* 1999;518:283–9.
- Wilson TA, Legrand A, Gevenois PA, De Troyer A. Respiratory effects of the external and internal intercostal muscles in humans. *J Physiol (Lond)* 2000;530:319–30.
- Wilson TA, De Troyer A. Respiratory effect of the intercostal muscles in the dog. *J Appl Physiol* 1993;75:2636–45.
- De Troyer A, Wilson TA. Coupling between the ribs and the lung in dogs. *J Physiol (Lond)* 2002;540:231–6.
- Greer JJ, Martin TP. Distribution of muscle fiber types and EMG activity in cat intercostal muscles. *J Appl Physiol* 1990; 69:1208–11.
- Sears TA. Efferent discharges in alpha and fusimotor fibres of intercostal nerves of the cat. *J Physiol (Lond)* 1964; 174:295–315.
- De Troyer A, Farkas GA. Contribution of the rib cage inspiratory muscles to breathing in baboons. *Respir Physiol* 1994;97:135–45.
- Taylor A. The contribution of the intercostal muscles to the effort of respiration in man. *J Physiol (Lond)* 1960; 151: 390–402.
- Delhez L. Contribution électromyographique à l'étude de la mécanique et du contrôle nerveux des mouvements respiratoires de l'homme. Liège: Vaillant-Carmanne; 1974.
- De Troyer A, Estenne M. Coordination between rib cage muscles and diaphragm during quiet breathing in humans. *J Appl Physiol* 1984;57:899–906.
- Bainton CR, Kirkwood PA, Sears TA. On the transmission of the stimulating effects of carbon dioxide to the muscles of respiration. *J Physiol (Lond)* 1978;280:249–72.
- Legrand A, De Troyer A. Spatial distribution of external and internal intercostal activity in dogs. *J Physiol (Lond)* 1999; 518:291–300.
- De Troyer A, Gorman R, Gandevia SG. Distribution of inspiratory drive to the external intercostal muscles in humans. *J Physiol (Lond)* 2003;546:943–54.
- Da Silva KMC, Sayers BMA, Sears TA, Stagg DT. The changes in configuration of the rib cage and abdomen during breathing in the anaesthetized cat. *J Physiol (Lond)* 1977;266:499–521.
- De Troyer A, Wilson TA. The canine parasternal and external intercostal muscles drive the ribs differently. *J Physiol (Lond)* 2000;523:799–806.
- Loring SH, Woodbridge JA. Intercostal muscle action inferred from finite-element analysis. *J Appl Physiol* 1991;70:2712–8.
- De Troyer A, Farkas GA, Ninane V. Mechanics of the parasternal intercostals during occluded breaths in the dog. *J Appl Physiol* 1988;64:1546–53.

44. De Troyer A. The inspiratory elevation of the ribs in the dog: primary role of the parasternals. *J Appl Physiol* 1991;70:1447–55.
45. Farkas GA, Decramer M, Rochester DF, De Troyer A. Contractile properties of intercostal muscles and their functional significance. *J Appl Physiol* 1985;59:528–35.
46. Road J, Newman S, Derenne JP, Grassino A. In vivo length–force relationship of canine diaphragm. *J Appl Physiol* 1986;60:63–70.
47. Farkas GA, Rochester DF. Functional characteristics of canine costal and crural diaphragm. *J Appl Physiol* 1988;65:2253–60.
48. Decramer M, Jiang TX, Demedts M. Effects of acute hyperinflation on chest wall mechanics in dogs. *J Appl Physiol* 1987;63:1493–8.
49. Jiang TX, Deschepper K, Demedts M, Decramer M. Effects of acute hyperinflation on the mechanical effectiveness of the parasternal intercostals. *Am Rev Respir Dis* 1989;139:522–8.
50. DiMarco AF, Romaniuk JR, Supinski GS. Mechanical action of the interosseous intercostal muscles as a function of lung volume. *Am Rev Respir Dis* 1990;142:1041–6.
51. Ninane V, Gorini M. Adverse effect of hyperinflation on parasternal intercostals. *J Appl Physiol* 1994;77:2201–6.
52. Decramer M, Kelly S, De Troyer A. Respiratory and postural changes in intercostal muscle length in supine dogs. *J Appl Physiol* 1986;60:1686–91.
53. Whitelaw WA, Ford GT, Rimmer KP, De Troyer A. Intercostal muscles are used during rotation of the thorax in humans. *J Appl Physiol* 1992;72:1940–4.
54. De Troyer A, Ninane V. Triangularis sterni: a primary muscle of breathing in the dog. *J Appl Physiol* 1986;60:14–21.
55. Hwang JC, Zhou D, St John WM. Characterization of expiratory intercostal activity to triangularis sterni in cats. *J Appl Physiol* 1989;67:1518–24.
56. Smith CA, Ainsworth DM, Henderson KS, Dempsey JA. Differential responses of expiratory muscles to chemical stimuli in awake dogs. *J Appl Physiol* 1989;66:384–91.
57. De Troyer A, Ninane V, Gilmartin JJ, et al. Triangularis sterni muscle use in supine humans. *J Appl Physiol* 1987;62:919–25.
58. Raper AJ, Thompson WT Jr, Shapiro W, Patterson JL Jr. Scalene and sternomastoid muscle function. *J Appl Physiol* 1966;21:497–502.
59. Gandevia SC, Leeper JB, McKenzie DK, De Troyer A. Discharge frequencies of parasternal intercostal and scalene motor units during breathing in normal and COPD subjects. *Am J Respir Crit Care Med* 1996;153:622–8.
60. De Troyer A, Kelly S. Action of neck accessory muscles on rib cage in dogs. *J Appl Physiol* 1984;56:326–32.
61. Legrand A, Schneider E, Gevenois PA, De Troyer A. Respiratory effects of the scalene and sternomastoid muscles in humans. *J Appl Physiol* 2003;94:1467–72.
62. De Troyer A, Estenne M, Vincken W. Rib cage motion and muscle use in high tetraplegics. *Am Rev Respir Dis* 1986;133:1115–19.
63. De Troyer A, Sampson M, Sigrist S, Kelly S. How the abdominal muscles act on the rib cage. *J Appl Physiol* 1983;54:465–9.
64. D'Angelo E, Prandi E, Bellemare F. Mechanics of the abdominal muscles in rabbits and dogs. *Respir Physiol* 1994;97:275–91.
65. Mier A, Brophy C, Estenne M, et al. Action of abdominal muscles on rib cage in humans. *J Appl Physiol* 1985;58:1438–43.
66. Koterba AM, Kosch PC, Beech J, Whitlock T. Breathing strategy of the adult horse (*Equus caballus*) at rest. *J Appl Physiol* 1988;64:337–46.
67. Farkas GA, Estenne M, De Troyer A. Expiratory muscle contribution to tidal volume in head-up dogs. *J Appl Physiol* 1989;67:1438–42.
68. Farkas GA, Schroeder MA. Mechanical role of expiratory muscles during breathing in prone anesthetized dogs. *J Appl Physiol* 1990;69:2137–42.
69. De Troyer A, Estenne M, Ninane V, et al. Transversus abdominis muscle function in humans. *J Appl Physiol* 1990;68:1010–16.
70. Abe T, Kusuhara N, Yoshimura N, Easton PA. Differential respiratory activity of four abdominal muscles in humans. *J Appl Physiol* 1996;80:1379–89.
71. Leever AM, Road JD. Mechanical response to hyperinflation of the two abdominal muscle layers. *J Appl Physiol* 1989;66:2189–95.
72. Estenne M, Pinet C, De Troyer A. Abdominal muscle strength in patients with tetraplegia. *Am J Respir Crit Care Med* 2000;161:707–12.

